

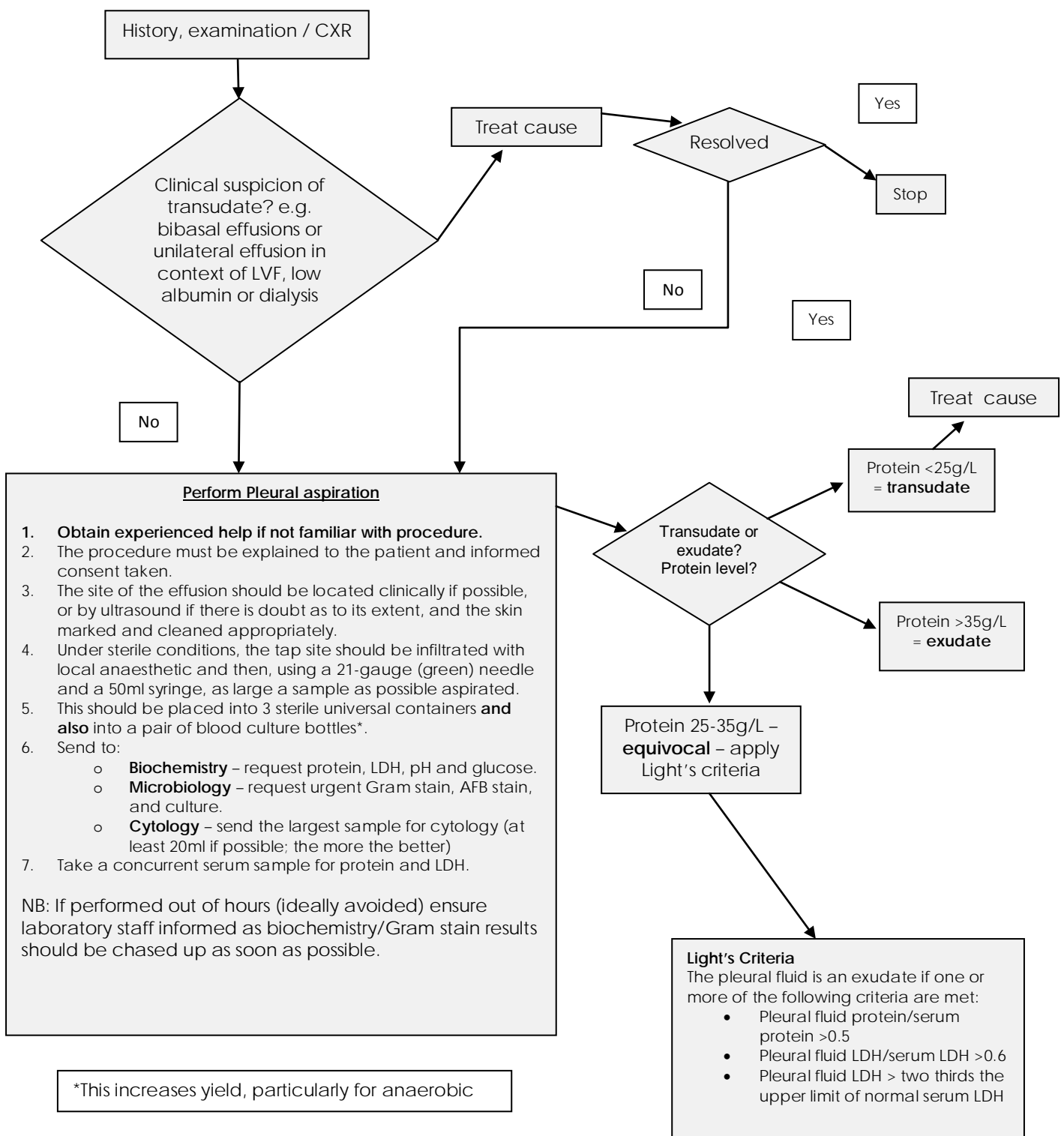


Title	Pleural Effusion Guideline
Document Type	Protocol
Issue no	GM/R003/01
Issue date	September 2014
Review date	September 2017
Distribution	BGH
Prepared by	Dr J F Faccenda
Developed by	Respiratory Medicine
Equality & Diversity Impact Assessed	

## BGH – pleural effusion guideline

Pleural effusions are an abnormal collection of fluid arising between the visceral and parietal pleura and are a common clinical finding which may be due to a wide range of pulmonary or systemic diseases. Consequently, the differential diagnosis of pleural effusions is wide ranging and a logical diagnostic approach is essential in order to avoid undue delay or unnecessary investigations.

The following diagnostic algorithm is adapted from current BTS guidelines and should be helpful in guiding the early investigation of a pleural effusion.



After performing the tap, ensure your documentation in the patient's notes is complete. Please use the pleural procedure bundle sticker. This should include a description of the appearance of the fluid aspirated. Once initial biochemistry and microbiology results are available they should also be entered in the patient's notes and the effusion classified as a transudate or exudate.

### Main causes of pleural effusions

<u>Transudates</u>	<u>Exudates</u>
<p><b>Commonest</b></p> <ul style="list-style-type: none"> <li>- Left ventricular failure</li> <li>- Liver cirrhosis</li> <li>- Hypoalbuminaemia</li> <li>- Peritoneal dialysis</li> </ul> <p><b>Less common</b></p> <ul style="list-style-type: none"> <li>- Hypothyroidism</li> <li>- Nephrotic syndrome</li> <li>- Mitral stenosis</li> <li>- Pulmonary embolism</li> </ul>	<p><b>Commonest</b></p> <ul style="list-style-type: none"> <li>- Malignancy</li> <li>- Parapneumonic effusion</li> </ul> <p><b>Less common</b></p> <ul style="list-style-type: none"> <li>- Pulmonary infarction</li> <li>- Rheumatoid arthritis</li> <li>- Autoimmune disease</li> <li>- Benign asbestos effusion</li> <li>- Pancreatitis</li> <li>- Post MI</li> </ul>

The type of pleural effusion (transudate/exudate) taken in context with the clinical picture, aspirate appearance and laboratory findings will usually give the diagnosis.

**Appearance** - Grossly bloody fluid is usually due to malignancy, pulmonary embolism causing infarction or trauma. A haematocrit can be performed on the pleural aspirate if there is concern that it may represent a haemothorax, this is confirmed if the haematocrit is more than half of that of the patient's peripheral blood. If frank pus is aspirated then an empyema is present which necessitates drainage. Turbid or milky effusions should be centrifuged to help distinguish between a chylothorax and empyema. Triglyceride levels can be measured if chylothorax is suspected.

**Protein and LDH** – Used to determine transudate/exudates.

**pH** – The principle clinical use of pH measurement is in identifying pleural infection. A pH of <7.2 indicates the need for a pleural drain. A low pH is also found in Rheumatoid effusions, oesophageal rupture and malignancy. In malignant pleural effusions, a low pH (<7.3) has been shown as a predictor of shorter survival.

**Glucose** – Low glucose measurements tend to be found in those effusions which also have a low pH, although a low pH is a better discriminator of

infection. The lowest glucose concentrations are found in rheumatoid effusions (typically <1.6mmol/L) and empyema.

**Amylase** – If pancreatitis is suspected as the cause, measurement of the pleural fluid amylase concentration may be helpful. Oesophageal rupture, ruptured ectopic pregnancy and pleural malignancy (10% of malignant effusions have a raised amylase) may also be responsible for an increase in levels.

**Cytology** – Cytology alone can diagnose pleural malignancy in only about 60% of cases. If malignancy is suspected and the first cytology sample is negative then a repeat sample should be sent. The larger the volume the better for cytology as it increases the diagnostic yield.

The next diagnostic step if the above information has not provided a firm diagnosis is to seek a respiratory opinion and perform a contrast enhanced CT thorax – senior medical staff advise when this is needed. Sometimes additional invasive investigations such as pleural biopsies ± CT/US guidance or thoracoscopy may be necessary to confirm a diagnosis or obtain a tissue diagnosis in the case of malignant effusions, or referral to the cardiothoracic surgical team.